

# Individualized Cortical Function Mapping Using High Gamma Activity

Tianyi Qian, Huaying Song, Weixuan Chen, Enhao Gong, Shangkai Gao and Bo Hong\*  
 Department of Biomedical Engineering, School of Medicine  
 Tsinghua University  
 Beijing, China

**Abstract**— How to reduce the risk of damaging the epilepsy patient's vital function areas during resection of epileptic focus remains a challenge for neurosurgeon. Clinically used electrical cortical stimulation (ECS) method shows limits on accuracy, efficiency and reliability. In this study, a cortical function mapping method with 3D visualization was implemented by analyzing and projecting the power change of high gamma (HG) oscillation in ECoG on patient's own MRI brain model. The method was tested on epilepsy patients with subdural electrodes for three tasks (hand movement, tongue movement and silent reading). The proposed 3D cortical function mapping on the patient's individual brain structure provides direct and accurate reference for resection surgery planning.

**Keywords**-- Cortical function; 3D mapping; MRI registration; Electrocorticography; high gamma oscillation

## I. INTRODUCTION

Epilepsy is a common chronic neurological disorder characterized by recurrent unprovoked seizures [1]. Although most epileptic seizures can be controlled by antiepileptic drugs (AEDs), there are still approximately 30% of the epilepsy sufferers cannot be cured by AEDs, and surgical operations must always be considered as viable option [2-4]. Before the lesion surgery, mapping of the patient's brain function is needed to define the position of the surgical lesion and the critical functional areas. At present, ECS has been applied as the 'Golden Standard' of cortical function mapping [5-8]. The surgical plan of resection can be made by evaluating the reaction of the patients as well as the phenomena such as the emergence of sensations, motions and language interruption evoked by the ECS in different cortical regions [9, 10]. However, there are several limitations for electrical stimulation: 1) the duration of a complete stimulation usually lasts hours, for the stimulation has to be undergone along with the changing and pairing of stimulated electrodes. 2) The intensity of the evoked phenomena are largely depended on the intensity and parameters of the stimulations and on the characteristics of individual cortex. 3) The ECS relies on patient compliance and cooperation that hardly be used in some cases. 4) Inappropriate operation and the lack of experience of the operators usually lead to erroneous "negative mapping". 5) After-discharge is also a negative point of ECS [11].

Although the application of neural imaging technology like fMRI and PET-CT enhances the accuracy of localization and provides the references for functional mapping, the electrophysiological organization of cortical function has not been well defined [12-15]. Recent studies using

electrocorticography (ECoG) recordings in human have shown that functional activation of cortex is associated with power increase of the high-gamma (HG, >60 Hz) oscillation. It has been found that HG power is highly correlated with the average firing rate recorded by the microelectrodes and was more sensitive to the changes of neuronal synchrony than firing rate [16, 17]. Cortical mapping can be concluded from spectral analysis of HG power recorded while the patients are performing certain tasks [18].

The common method using 2-dimension (2D) standard brain model for mapping cannot co-register the functional regions with the record electrodes. Adding the existence of individual differences and the cortical pathological changes, function mapping on individual brain is necessary to provide enough information and explicit guidance for surgery planning. In recent years, the real-time mapping of cortical function using ECoG has been brought into attention. This technique could potentially provide a powerful tool in delineating cortex function areas [19, 20].

Subdural electrodes are usually implanted in the patients with intractable epilepsy before resection surgery, which provides a chance of chronic recording of cortical activities. In this study, the cortical function mapping and visualization software was developed to localize the cortical function from power spectrum analysis of ECoG, and to map the high gamma power changes on the patients' individual cortex. The high gamma activity from the implanted electrodes was obtained when the subject was performing certain tasks, such as hand, tongue movement and silent reading. The feasibility of the system was demonstrated by one subject data, showing consistent functional localization with other neural imaging studies.

## II. METHODS

Fig. 1 shows the block diagram of the system which consists of five components: (1) MRI and CT image co-registration, (2) Extraction of electrode coordinates in CT images, (3) MRI image segmentation and reconstruction, (4) ECoG signal processing (5) 3D mapping and visualization. This software package was developed in Visual Studio 2008 with C# language. Some functions in this system inherited the .net components of Visualization Toolkit (VTK, <http://www.vtk.org/>) and Insight Toolkit (ITK,

<http://www.itk.org/>).

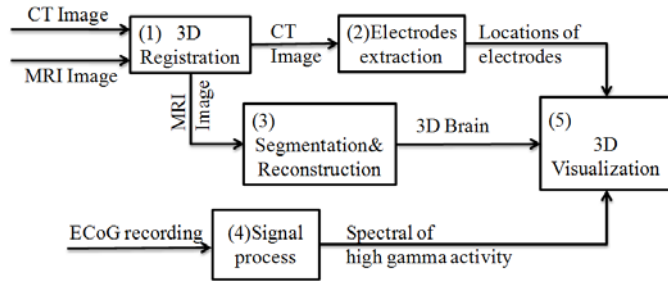


Figure 1. Block diagram of the system

### A. CT and MRI co-registration

Since the implanted electrodes can only be determined from post-operative CT scans, in order to mark electrodes on the patient's individual cortical surface, the post-operative CT should co-register with the pre-operative MRI in three-dimensional model. Co-registration of CT and MRI was achieved by selecting fiducial points [21] and calculating a transformation matrix. After co-registration, the coordinates of CT can be mapped to the MRI coordinate system. To improve the accuracy of co-registration, the 3D volume data of different modality should be pre-processed to unify the x, y, z axis direction and origin of coordinates.

Usually, fiducial points are anatomy or symptoms markers, including eyebrow center, the tip of the nose, theinion, calvaria and the pre-auricular fossa etc. It is necessary to unify the distribution of fiducial points, which is better at the contour of the model. Co-registration allowed rigid transformation because the CT and MRI images belong to the same patient. Since there is no obvious structure deformation, the model can be rescaled and rotated by a linear transformation matrix. Suppose the coordinates of CT are  $(x_n, y_n, z_n)$  and the coordinates of MRI are  $(h_n, m_n, n_n)$ . Their relationship with the transformation matrix is:

$$\begin{bmatrix} x_n & y_n & z_n \end{bmatrix} \begin{bmatrix} a_1 & a_2 & a_3 \\ b_1 & b_2 & b_3 \\ c_1 & c_2 & c_3 \end{bmatrix} = \begin{bmatrix} h_n & m_n & n_n \end{bmatrix} \quad (1)$$

The n groups of coordinates of fiducial points were substituted into the formula, forming three groups of over-determined equations, each with n equations and 3 unknowns. To reduce the manual operation error of fiducial point selection and the co-register residue, it is better to solve the ternary linear equation with more than three fiducial points, which poses a least-squares problem [22].

### B. Electrode coordinates extraction

The location of electrodes were extracted from the three views of CT reconstructed model (the white points in CT scans shown in Fig. 2). And then, the electrode's position in CT coordinates can be translated into MRI's by multiplying the transformation matrix.

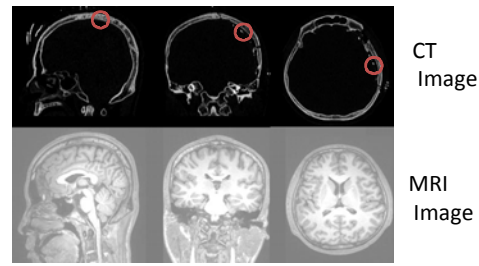


Figure 2. The post-operative CT and the pre-operative MRI scans, with red circles indicating the implanted electrode.

### C. MRI segmentation and reconstruction

The three-dimensional cortex segmentation in MRI head model was achieved with region growing algorithm of ITK. After cortex segmentation, the cortex model was saved as VtkPolyData format to be shown with reconstructed electrodes.

### D. Experiment paradigm and ECoG analysis

The block design protocol widely used in fMRI study was adopted in our paradigm. In the beginning of each block, subject was asked to relax without any movements for 10 seconds. After that, there was a text command showing on the screen to instruct the subject to perform hand open-close, tongue movement and silent reading. 3 blocks were obtained for each type of the brain function mapping. Potentials were sampled at 1024Hz, using 128-channel long term EEG monitoring system (Bio-Logic®, USA). A clinical subdural electrode was used as the ground and binaural electrodes as reference. The time-frequency distribution of each block was calculated by using short-time Fourier transform with 1s sliding window and 30ms step. The baseline was selected as the 4s before text command onset to translate the time-frequency distribution into spectral power change. The average power change of each time-frequency point with respect to the baseline in HG band was chosen as the characteristic value. Prominent increase of HG power indicates that the corresponding cortical areas are involved in the function of the task the subject is performing.

### E. Three-dimensional visualization

The power change of HG oscillation  $s(t, x, y, z)$  was mapped to the cortex surface by 3D interpolation with linear superposition of Gaussian distribution [23]. Suppose the electrode's coordinates are  $(x_i, y_i, z_i)$  and the HG activity of each electrode at the time t is  $p_i(t)$ . To any points  $(x, y, z)$  on the 3D surface of the cortex, the  $s(t, x, y, z)$  is:

$$s(t, x, y, z) = \sum_{i=1}^n p_i(t) \cdot w_i \quad (2)$$

$$w_i = \frac{1}{\sqrt{2\pi\sigma}} e^{-\frac{(x-x_i)^2 + (y-y_i)^2 + (z-z_i)^2}{2\sigma^2}} \quad (3)$$

( $\sigma$  is the variance of the Gaussian distribution.)

Due to the enormous number of points in the 3D cortex model needed to be refreshed, the template method was

adopted to reduce the time cost for calculation so that the mapping result can be updated in real-time. The template is an array which contains the value of  $w_i$  for each point. Therefore the calculation of  $s(t)$  is simplified from repeated exponent arithmetic to find the  $w$  from the template array. This approach greatly reduced the image updating time with an average of 98%. With data streaming function of the EEG amplifier, real-time mapping was also implemented.

### F. Materials

A 19-year-old epilepsy patient with subdural electrodes covering the frontal lobe, temporal lobe, parietal lobe and partial occipital lobe in the left cerebral hemisphere. Before implantation surgery, MRI imaging was conducted on a 3T Siemens ALLEGRA scanner. 176 axial slices (1mm thickness with 1.00\*1.00 mm in-plane resolution), covering the whole brain, were collected with a head coil. After the surgery for electrodes implant, the 3D head CT image was obtained by the Siemens SOMATOM Sensation 64 CT with 186 slices (1mm thickness with 0.4\*0.4 mm in-plane resolution). There were three tasks in the whole test including hand open-close, tongue movement and silent reading. The subjects gave written informed consent to participate the experiment and the protocol was approved by the Ethics Committee of the second affiliated hospital of Tsinghua University.

## III. RESULTS

The 7 fiducial points were selected in 5 different areas including the eyebrow center,inion, left cerebra outside edge, right cerebra outside edge and calvaria (2 points in the inion and calvaria area respectively) in CT and MRI data. With the registration matrix, it is able to accomplish the coordinate transferring from CT electrode coordinate system to MRI coordinates to provide the electrode positions on MRI image.

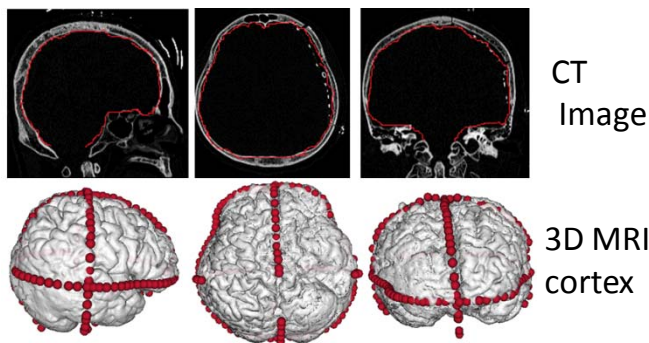


Figure 3. Inner contour of skull (the red point in the CT image showing as red ball in 3D MRI cortex with co-register coordinates)

The registration results can be evaluated by mapping the inner contour of skull on the MRI cerebral cortex model and then measuring whether they are coincide with each other. The registration result is shown in Fig. 3, which has been calibrated by 30 contour points with average error of 2.6mm.

The electrodes (red ball in Fig. 4) have been marked on the cortex segmented from T2 weighted MR images. After analyzing the HG power changes of each electrode, those active areas for each task were indentified. Active electrodes and non-active ones showed distinct HG dynamics during task performing.

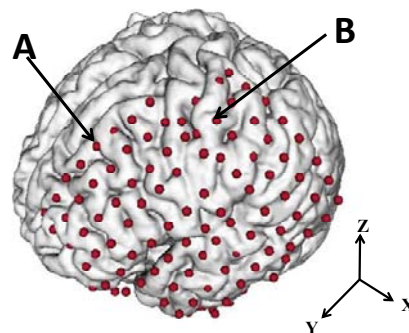


Figure 4. The segmentation and reconstruction result of cerebral cortex with electrodes marked as red ball.

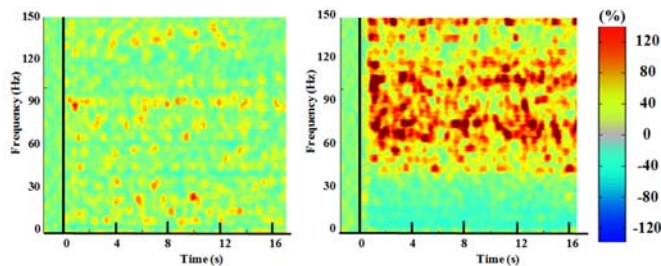


Figure 5. The time-frequency distribution of the electrode A (left) and B (right) labeled in the Fig. 4.

Fig. 5 shows the time-frequency distribution of two electrodes, in which the power of electrode B increased significantly within the frequency band of 60-150Hz. However, the power change is more distinct from 60 to 90Hz, so we use the average power change ratio in this band as the input for 3D visualization on MRI image.

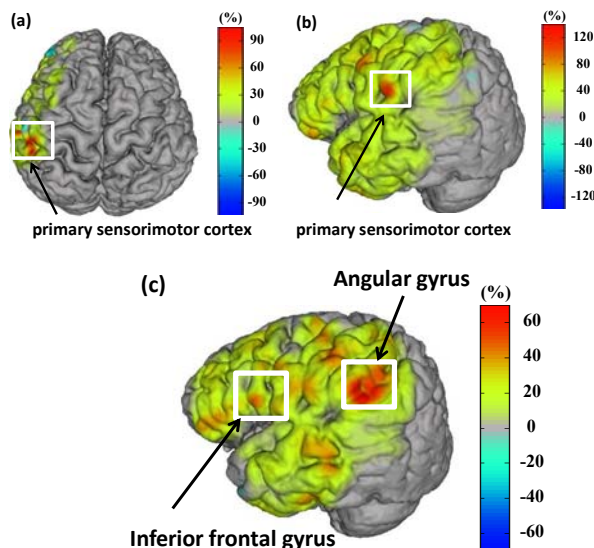


Figure 6. The functional mapping result of the hand open-close task(a), the tongue movement task(b)and the silent reading task(c).

Fig. 6 displays the mapping result of HG activation on the subject's own cortex, in which red color indicates a significant increase of HG power during the task. The HG activities of

designated three tasks were mapped respectively. It is shown that the hand and tongue movement activate the area around central gyrus which is part of the primary sensorimotor cortex. The more lateral localization of tongue movement than hand movement is consistent with fMRI findings [24]. The silent reading task activated the angular gyrus largely and the inferior frontal gyrus slightly, covering Wernicke's area and Broca's area and their vicinity. Previous fMRI imaging study of speech validates our mapping result as well [25]. For better comparison, the cortex photo taken during the surgery and the cortical function mapping on the 3D reconstructed cortex are shown in Fig. 7. The precise localization of tongue movement function is clearly shown which provides a vivid reference for surgery planning.

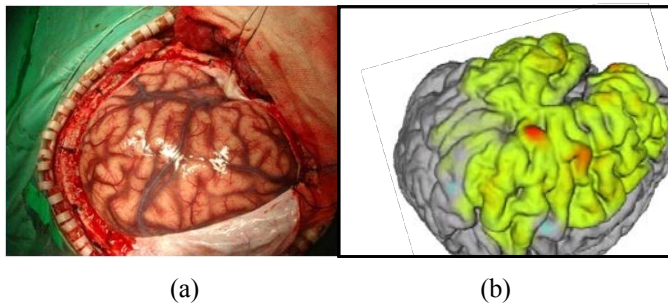


Figure 7. Comparison between the surgery photo(a) and the cortical function mapping result (b).

#### IV. DISCUSSION & CONCLUSION

Cortical function mapping has been a classical and fascinating question, which was systematically explored by Penfield et al on epilepsy patients [26]. However, modern neural imaging studies have gradually revealed the individual differences and the complexity of functional localization [27], which prompts the need of individualized cortical function mapping. In practice, using fMRI, PET and other functional mapping methods has the issue of low spatial resolution, high expense, time consumption and difficulty of quality control in clinical environment.

In this study, for the purpose of neural surgery planning, the three-dimensional MRI image were coupled with high gamma electrical activity to implement an individualized cortical function mapping, which for the first time provides both high spatial resolution and temporal dynamics of direct neural activity. The proposed cortical functional imaging approach bears several advantages. Firstly, functional mapping via analyzing the ECoG power changes during patients performing tasks is able to fulfill cortical mapping more accurately as well as to avoid electrical stimulation on human brain. Secondly, the operation time of this method is much shorter than that of electrical stimulation, which usually takes about 5 minutes on average to get the map of a specific function. Finally, the cortical functional map is displayed on the patient's own cortex structure and can be virtually rotated and adjusted in 3D space, which provides notable convenience and intuition for neurosurgeon's resection planning. If MRI-compatible electrodes are adopted, a post-operative MRI scan can easily substitute for the step of registration, for then electrodes can be directly marked out in the MRI images. As shown in Fig. 8,

two rows of deep MRI-compatible electrodes were inserted into hippocampus and visualized as red balls.

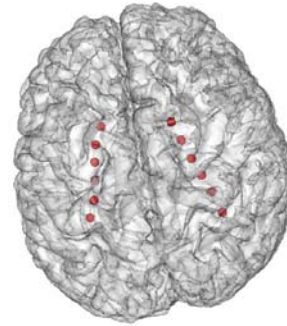

Figure 8. 3D visualization of deep MRI-compatible electrodes (red balls).

Compared to the result of electrical stimulation, it is found that the high gamma ECoG based mapping is more capable of reflecting the regional activity of functional areas. In contrast, accounting for the spread effect of electric current and the mode of paired stimulation, electrical stimulation usually enlarges the resulting area of functional mapping, which will lead to a certain false positive rate.

#### ACKNOWLEDGMENT

This work was partly supported by National Natural Science Foundation of China (Project 30630022) and Tsinghua University Initiative Scientific Research Program 2009THZ02126. The author would like to thank the surgical team in the second affiliated hospital of Tsinghua University for patient cares and image data collection.

#### REFERENCES

- [1] Guidelines for epidemiologic studies on epilepsy. Commission on Epidemiology and Prognosis, International League Against Epilepsy., *Epilepsia*, vol. 34, (no. 4), 1993, pp. 592-6.
- [2] A. McTague and R. Appleton, *Treatment of difficult epilepsy.*, Arch Dis Child, 2010.
- [3] J.W. Sander, Some aspects of prognosis in the epilepsies: a review., *Epilepsia*, vol. 34, (no. 6), 1993, pp. 1007-16.
- [4] I. Fried, A. Katz, G. McCarthy, K.J. Sass, P. Williamson, S.S. Spencer, and D.D. Spencer, Functional organization of human supplementary motor cortex studied by electrical stimulation., *J Neurosci*, vol. 11, (no. 11), 1991, pp. 3656-66.
- [5] H.W. Lee, S.B. Hong, D.W. Seo, W.S. Tae, and S.C. Hong, Mapping of functional organization in human visual cortex: electrical cortical stimulation., *Neurology*, vol. 54, (no. 4), 2000, pp. 849-54.
- [6] H. Luders, R.P. Lesser, J. Hahn, D.S. Dinner, H. Morris, S. Resor, and M. Harrison, Basal temporal language area demonstrated by electrical stimulation., *Neurology*, vol. 36, (no. 4), 1986, pp. 505-10.
- [7] P.G. Simos, A.C. Papanicolaou, J.I. Breier, J.W. Wheless, J.E. Constantinou, W.B. Gormley, and W.W. Maggio, Localization of language-specific cortex by using magnetic source imaging and electrical stimulation mapping., *J Neurosurg*, vol. 91, (no. 5), 1999, pp. 787-96.
- [8] R.P. Lesser, H. Luders, G. Klem, D.S. Dinner, H.H. Morris, J.F. Hahn, and E. Wyllie, Extraoperative cortical functional localization in patients with epilepsy., *J Clin Neurophysiol*, vol. 4, (no. 1), 1987, pp. 27-53.
- [9] K. Vonck, P. Boon, L. Goossens, S. Dedeurwaerdere, P. Claeys, F. Gossiaux, P. Van Hese, T. De Smedt, R. Raedt, E. Achten, K. Deblaere, A. Thielemans, P. Vandemaele, E. Thiery, G. Vingerhoets, M. Miatton, J. Caemaert, D. Van Roost, E. Baert, G. Michielsens, F. Dewaele, K. Van Laere, V. Thadani, D. Robertson, and P. Williamson, Neurostimulation for refractory epilepsy., *Acta Neurol Belg*, vol. 103, (no. 4), 2003, pp. 213-7.

- [10] E. Mandonnet, P.A. Winkler and H. Duffau, Direct electrical stimulation as an input gate into brain functional networks: principles, advantages and limitations., *Acta Neurochir (Wien)*, vol. 152, (no. 2), 2010, pp. 185-93.
- [11] P.R. Jolles, P.R. Chapman and A. Alavi, PET, CT, and MRI in the evaluation of neuropsychiatric disorders: current applications., *J Nucl Med*, vol. 30, (no. 10), 1989, pp. 1589-606.
- [12] A. Qureshy, R. Kawashima, M.B. Imran, M. Sugiura, R. Goto, K. Okada, K. Inoue, M. Itoh, T. Schormann, K. Zilles, and H. Fukuda, Functional mapping of human brain in olfactory processing: a PET study., *J Neurophysiol*, vol. 84, (no. 3), 2000, pp. 1656-66.
- [13] M.P. Richardson, Epilepsy and surgical mapping., *Br Med Bull*, vol. 65, 2003, pp. 179-92.
- [14] H. Stefan, G. Pawlik, H.G. Bocher-Schwarz, H.J. Biersack, W. Burr, H. Penin, and W.D. Heiss, Functional and morphological abnormalities in temporal lobe epilepsy: a comparison of interictal and ictal EEG, CT, MRI, SPECT and PET., *J Neurol*, vol. 234, (no. 6), 1987, pp. 377-84.
- [15] N.E. Crone, D.L. Miglioretti, B. Gordon, and R.P. Lesser, Functional mapping of human sensorimotor cortex with electrocorticographic spectral analysis. II. Event-related synchronization in the gamma band., *Brain*, vol. 121 ( Pt 12), 1998, pp. 2301-15.
- [16] T. Blakely, K.J. Miller, R.P. Rao, M.D. Holmes, and J.G. Ojemann, Localization and classification of phonemes using high spatial resolution electrocorticography (ECoG) grids., *Conf Proc IEEE Eng Med Biol Soc*, vol. 2008, 2008, pp. 4964-7.
- [17] N. Nakasato, M.F. Levesque, D.S. Barth, C. Baumgartner, R.L. Rogers, and W.W. Sutherling, Comparisons of MEG, EEG, and ECoG source localization in neocortical partial epilepsy in humans., *Electroencephalogr Clin Neurophysiol*, vol. 91, (no. 3), 1994, pp. 171-8.
- [18] G.H. Barnett, D.W. Kormos, C.P. Steiner, and H. Morris, Registration of EEG electrodes with three-dimensional neuroimaging using a frameless, armless stereotactic wand., *Stereotact Funct Neurosurg*, vol. 61, (no. 1), 1993, pp. 32-8.
- [19] M. Wu, K. Wisneski, G. Schalk, M. Sharma, J. Roland, J. Breshears, C. Gaona, and E.C. Leuthardt, Electrocorticographic frequency alteration mapping for extraoperative localization of speech cortex., *Neurosurgery*, vol. 66, (no. 2), 2010, pp. E407-9.
- [20] P. Brunner, A.L. Ritaccio, T.M. Lynch, J.F. Emrich, J.A. Wilson, J.C. Williams, E.J. Aarnoutse, N.F. Ramsey, E.C. Leuthardt, H. Bischof, and G. Schalk, A practical procedure for real-time functional mapping of eloquent cortex using electrocorticographic signals in humans., *Epilepsy Behav*, vol. 15, (no. 3), 2009, pp. 278-86.
- [21] PH Schoenemann, RM Carroll. Fitting one matrix to another under choice of a central dilation and a rigid motion. *Psychometrika* 1970; 35: 245-55.
- [22] D.L. Hill, D.J. Hawkes, J.E. Crossman, M.J. Gleeson, T.C. Cox, E.E. Brace, A.J. Strong, and P. Graves, Registration of MR and CT images for skull base surgery using point-like anatomical features., *Br J Radiol*, vol. 64, (no. 767), 1991, pp. 1030-5.
- [23] P. HECKBERT Color image quantization for frame buffer display. *ACM SIGGRAPH Computer Graphics*, 1982, 16(3): 297-307.
- [24] A. Righini, O. de Divitiis, A. Prinster, D. Spagnoli, I. Appollonio, L. Bello, P. Scifo, G. Tomei, R. Villani, F. Fazio, and M. Leonardi, Functional MRI: primary motor cortex localization in patients with brain tumors., *J Comput Assist Tomogr*, vol. 20, (no. 5), 1996, pp. 702-8
- [25] S.M. Rao, J.R. Binder, P.A. Bandettini, T.A. Hammeke, F.Z. Yetkin, A. Jesmanowicz, L.M. Lisk, G.L. Morris, W.M. Mueller, L.D. Estkowski, and A. Et, Functional magnetic resonance imaging of complex human movements., *Neurology*, vol. 43, (no. 11), 1993, pp. 2311-8.
- [26] C.J. Price, The anatomy of language: a review of 100 fMRI studies published in 2009., *Ann N Y Acad Sci*, vol. 1191, (no. 1), 2010, pp. 62-88.
- [27] K.M. Swallow, T.S. Braver, A.Z. Snyder, N.K. Speer, and J.M. Zacks, Reliability of functional localization using fMRI., *Neuroimage*, vol. 20, (no. 3), 2003, pp. 1561-77.